

# Surgical Management of Advanced Degenerative Arthritis of Temporomandibular Joint With Metal Fossa-Eminence Hemijoint Replacement Prosthesis: An 8-Year Retrospective Pilot Study

*Jinkyu Park, DDS, PhD,\* Eugene E. Keller, DDS, MSD,† and Kevin I. Reid, DMD, MS,‡*

**Purpose:** The purpose of this study was 2-fold: to evaluate the surgical outcome and surgical morbidity of the temporomandibular joint (TMJ) metal fossa-eminence hemijoint prosthesis replacement, implanted in patients with degenerative arthritis, and to establish whether future, more rigorous clinical trial assessment of the hemijoint replacement is warranted.

**Materials and Methods:** Eighty-four patients (79 females and 5 males) involving 108 joints (60 unilateral, 24 bilateral) were operated on, and 112 joint metal fossa-eminence prostheses were placed. Information was gathered from patient response questionnaires and clinicoradiographic medical chart review. Change in pain intensity (preoperative versus current) was measured by 2 methods: 1) pain experience (1 to 6) and 2) pain intensity (visual analog scale, 1 to 10). Chewing ability, jaw opening, and joint noise were evaluated (visual analog scales, 1 to 10). Surgical morbidity and implant survival were documented.

**Results:** The average period from initial TMJ symptoms to metal fossa-eminence implant surgery was 12.3 years. The average number of previous TMJ surgeries was 1.9. Pain was reduced 56% and 61.2% by 2 methods. Chewing ability, jaw opening, and joint noise were improved by 53.4%, 50.2%, and 64%, respectively. Nine of 112 implants were explanted during the study period. Patient satisfaction for the clinical outcome was 8.3 on a scale of 0 to 10.

**Conclusion:** The surgical placement of the Co-Cr-Mo metal fossa-eminence prosthesis (partial joint replacement) provides significant focal preauricular pain relief and reduces TMJ dysfunction secondary to advanced degenerative arthritis. The results of this case series supports further investigation of this form of surgical management in a rigorously controlled prospective fashion.

© 2004 American Association of Oral and Maxillofacial Surgeons  
*J Oral Maxillofac Surg* 62:320-328, 2004

---

\*Visiting Clinician, Division of Oral and Maxillofacial Surgery, Mayo Clinic, Rochester, MN.

†Consultant and Chair, Division of Oral and Maxillofacial Surgery, Department of General Surgery, and Professor, Mayo Medical School, Rochester, MN.

‡Consultant and Chair, Orofacial Pain, Department of Dental Specialties, Consultant, Anesthesia Pain Center, and Assistant Professor, Mayo Medical School, Rochester, MN.

Address correspondence and reprint requests to Dr Keller: Mayo Medical Clinic, 200 First St SW, Rochester, MN 55905; e-mail: Keller.Eugene@mayo.edu

© 2004 American Association of Oral and Maxillofacial Surgeons  
0278-2391/04/6203-0013\$30.00/0  
doi:10.1016/j.joms.2003.08.016

Pain in the focal preauricular region is the most common complaint of patients presenting for surgical management of advanced degenerative arthritis of the temporomandibular joint (TMJ). Nonsurgical treatment with intraoral splints, physical therapy, behavior modification to reduce aggravating factors, medication, arthrocentesis, and other treatment is accomplished with varying success in this patient population.<sup>1</sup> Although these nonsurgical treatments often provide efficient or definitive means of managing advanced degenerative arthritis, they may fall short in providing consistent pain relief and functional jaw improvement. Pain reduction is the most important goal in improving the patient's quality of life and returning him or her to normal daily activity. Goals related to masticatory function are im-

portant but are less important than persistent, unremitting pain. Historically, surgical treatment of advanced degenerative arthritis of the TMJ follows failed nonsurgical therapy, and likewise aggressive surgical therapy (partial or total joint replacement) frequently follows more conservative surgical therapy (disc repair or autologous or alloplastic disc replacement).<sup>2-6</sup>

Autogenous graft materials such as cartilage, dermis, fascia, or muscle are used by surgeons as a replacement for the absent disc in patients with advanced degenerative TMJ disease.<sup>7-12</sup> These interpositional autogenous graft materials reportedly act to eliminate bone-on-bone contact and allow the osseous structures (fossa, eminence, and condyle) to heal and remodel according to functional demands. It is the authors' opinion that long-term outcome of autogenous tissue disc replacement has been highly variable and unpredictable. Where previous multiple TMJ operations have been performed, the record of autogenous (or allogenic) disc reconstruction is consistently unsuccessful.<sup>13</sup> This compromised record is due to numerous factors, including coexisting foreign body giant cell reaction, exuberant scar tissue formation, persistence of central nerve injury (neuropathic) pain, and compromised blood supply to the surgical site. In addition, these interpositional autogenous soft tissue grafts and soft allogenic materials do not survive the vigorous joint mechanics; they are mechanically shredded and eventually resorbed or metabolized by the body's immune system.<sup>14</sup>

In the field of orthopedic surgery, there are numerous reports describing joint reconstruction prostheses.<sup>15,16</sup> Although those materials and designs are used successfully in the hip or knee joint reconstruction, they cannot necessarily be applied to the TMJ because the functional biomechanics and anatomy of the TMJ are significantly different in multiple dimensions: 1) bilateral translation as well as rotational motion, which produces unique loading mechanics; 2) loading modulation by the natural dentition or replacement dental prosthesis; 3) presence of a mobile dynamic disc; 4) limited anatomic space surrounded by high surgical risk anatomic structures; and 5) frequent awake and sleep-related excessive joint loading (clenching, bruxing).

For partial joint reconstruction of advanced degenerative arthritis of the TMJ, various allogenic prostheses have been reported. Generally, the allogenic TMJ prostheses function as replacement for 1 of 3 structures: disc, fossa-eminence, or condyle. For replacement of the disc, allogenic materials including various silicone products have been used with disappointing outcome.<sup>17,18</sup> All of the soft allogenic disc replacements have major disadvantages and have been removed from the market.<sup>14,17</sup> The metal fossa-eminence replacement that functions against a native

condyle has produced positive therapeutic gains for patients with or without a residual disc.<sup>19-21</sup> The authors have used only the metal fossa eminence in patients without a functional disc.<sup>19-21</sup>

At this time, the literature does not clearly establish the surgical indications for a hemijoint versus a total joint prosthesis for the treatment of advanced degenerative arthritis of various etiologies, especially in the multioperated patient. For total joint reconstruction, the fossa-eminence and condyle are replaced in post-traumatic, oncologic, or advanced degenerative arthritis conditions. Although many designs and materials have been used, both the overall bulk in a limited anatomic site surrounded by vital structures and mechanical failure continue to limit success in this field.<sup>20,22-28</sup> The partial joint replacement with the metal fossa-eminence, rather than the total joint replacement, became an attractive treatment option for the authors for the severely compromised patient, who presented for treatment after failure of other surgical procedures, especially in the multioperated patients. The previous reported success of the Christensen metal fossa-eminence implant (Christensen TMJ Implant System; TMJ Implant Inc, Golden, CO) and the relatively minimal surgical intervention were initial reasons to embark on this surgical path.<sup>19,29-31</sup>

We initially speculated that a metal fossa-eminence prosthesis can function against recontoured native residual condylar bone and chose to use a metal fossa-eminence hemijoint prosthesis alone for treating moderately or severely compromised and symptomatic patients with advanced degenerative joint disease (absent disc, bone-on-bone contact). The metal prosthesis acts as an interpositional material. The bony fossa and eminence are debrided and recontoured for insertion of a low-profile nonanatomic metal fossa-eminence prosthesis. The condyle is reshaped in most patients to allow minimal osseous contact on the metal fossa and no eminence obstruction during translational condyle motion. Aggressive patient muscle-activated mandibular motion is performed by the patient during a 3-month healing period. This active opening motion provided by the muscles of mastication does not load the hemijoint reconstruction and is similar to the passive motion described by Salter<sup>28</sup> instituted in major joints after surgery.

## Materials and Methods

### PATIENT SELECTION

Eighty-four consecutively operated patients (1992-1999) were selected for this study from the records of Mayo Medical Center, Rochester, MN. They had undergone arthroplasty with placement of a Co-Cr-Mo glenoid fossa-eminence prosthesis (Christensen TMJ

**TABLE 1. QUESTIONNAIRE DATA COLLECTION**

Pain (1): Check 0 to 6 that describes your pain experience (0 = no pain).

- 1 = some pain, which you can easily disregard
- 2 = some pain, which you cannot disregard but does not make your usual activities more difficult
- 3 = pain that makes concentration on a more demanding task more difficult
- 4 = pain that makes most things you do more difficult except the most basic
- 5 = pain that is so severe that you have to rest
- 6 = pain that is so severe you cannot stand it

Pain (2): Check 1 to 10 on the visual analog scale (VAS) below indicating facial or jaw pain experience (0 = no pain, 10 = severe, intense, incapacitating pain).

Place A on VAS of your pain before temporomandibular joint surgery and B of your current facial or jaw pain.

Chewing ability: Check 1 to 10 on the VAS indicating your experience (0 = no problem, 10 = impossible to chew).

Place A on VAS of your chewing ability before surgery and B of your chewing ability after surgery.

Jaw opening: Check 1 to 10 on the VAS below indicating your experience (0 = no opening problem, 10 = no opening).

Place A on VAS of your jaw opening before surgery and B of your current opening.

Joint noise: Check 1 to 10 on the scale indicating your experience (0 = no noise, 10 = severe annoying noise).

Place A on VAS of your joint noise before surgery and B of your current noise.

Satisfaction with surgical result: Check 1-10 on the VAS indicating your experience (0 = no satisfaction, 10 = complete satisfaction).

Additional questions were:

What problems did you experience immediately after surgery?

- a. Difficulty raising eyebrow, Yes\_\_\_, No\_\_\_, How long\_\_\_months.
- b. Change in bite, Yes\_\_\_, No\_\_\_, How long\_\_\_months.

Implant System) via the preauricular approach. To control consistent surgical technique and treatment protocol, consecutive patients of one surgeon (E.E.K.) were studied. Indications for surgery were 1) focal preauricular pain, often accompanied by headache, limited jaw motion, compromised mastication, and TMJ crepitus (coexisting masticatory myofascial pain and neuropathic pain were common) and 2) degenerative joint disease or fibro-osseous ankylosis documented by clinical and radiographic means. No efforts were made to distinguish primary and secondary degenerative arthritis in this study cohort. All patients had 1) a history of persistent and significant pain and functional impairment after nonsurgical therapy or surgical (frequently multiple) intervention; 2) clinically and radiographically documented advanced degenerative joint disease or fibro-osseous ankylosis; 3) marked loss or hypertrophy of osseous cortical and cancellous bone anatomy with collapse of joint space; and 4) failure to obtain adequate analgesia with comprehensive nonsurgical treatments, including medications, occlusal splints, physical therapy, behavior modification, or arthrocentesis. Prior surgery was common and highly variable and included numerous types of implanted autogenous grafts or allogenic materials (see Results).

#### DATA COLLECTION

Information about the patient's previous treatment, current surgical management, and postsurgical treatment were obtained from the Mayo Medical records. A standardized questionnaire was completed by the

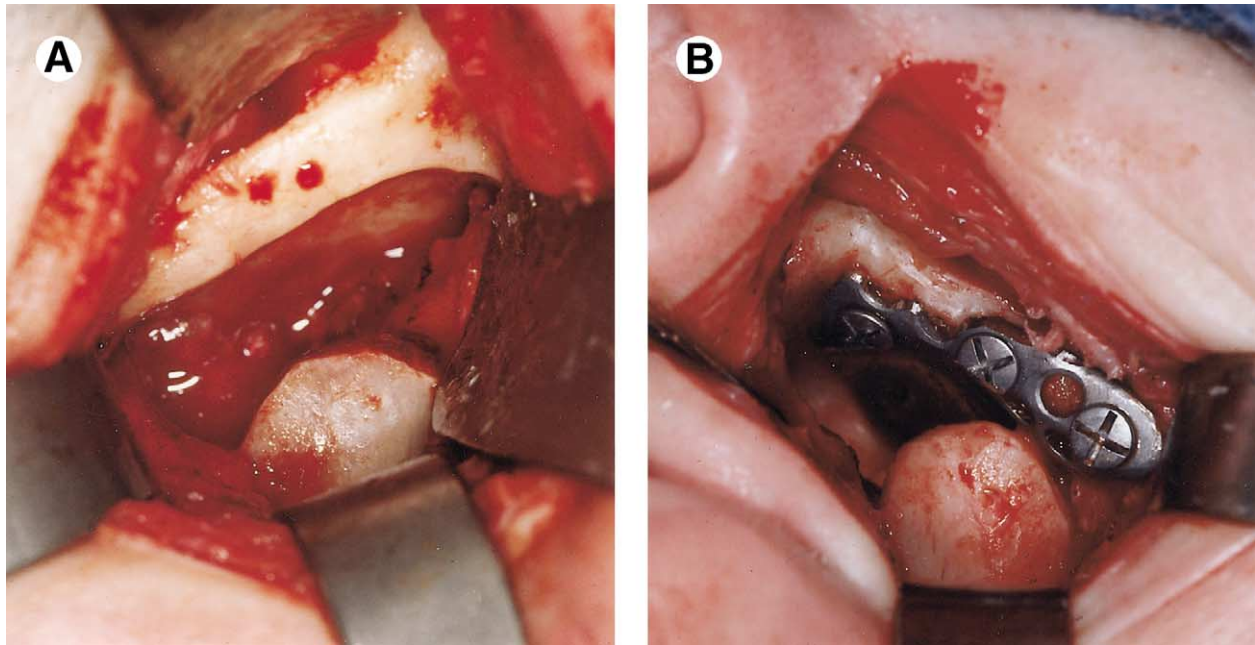
patient at his or her most recent examination or via mail (Table 1).

#### DATA ANALYSIS TECHNIQUE

The data gathered from the clinical examination, chart review, and questionnaire were shown as frequency, mean  $\pm$  SEM, and range. The pain and the functional capability were analyzed by mean values, *t* test (level of significance was  $P < .01$ ), and 1-way analysis of variance with factorial experimental type (Scheffé F test: multicomparison significance level was 95) to compare the difference between preoperative and postoperative findings.

#### SURGICAL TECHNIQUE

The same surgical technique was used in all patients by one surgeon (E.E.K.) (Fig 1). After administration of nasal endotracheal general anesthesia, the TMJ is exposed through via preauricular incision. The glenoid fossa is entered by subperiosteal dissection and exposed from lateral to medial. The posterior condylar surface is exposed by blunt dissection, and the superior condyle is then exposed by subperiosteal dissection. Condyle and fossa-eminence osteophytes or osseous irregularities are removed by high-speed rotary bur. The entire articular eminence (lateral to medial) is reduced to a gentle inclination. If there is need for more space for the metal prosthesis, further condyle height reduction (1 to 3 mm) is accomplished with a high-speed bur. The medial (or inner) condyle pole is significantly reduced in a majority of patients. The fossa-eminence prosthesis is selected



**FIGURE 1.** Surgical technique. A, Preparation of articular fossa, eminence, and condyle for metal fossa-eminence prosthesis. B, Metal fossa-eminence prosthesis in position and stabilized by lateral fossa cortex screws.

and filled. Prosthesis stability is then checked by observing for evidence of motion during functional movement of the condyle. The metal fossa is then secured with 2 or 3 bone screws placed in the lateral fossa cortex. The wound is debrided thoroughly with saline and closed in layers. In recent patients, autologous abdominal fat is harvested and placed into peri-joint dead space before wound closure. An ice compress is used during the first 24 to 48 hours after surgery. Intravenous antibiotics are given intraoperatively and postoperatively during hospitalization (24 to 48 hours). Oral antibiotics were given 1 week postoperatively.

Active opening jaw motion initiated by patient's masticatory musculature is started immediately postoperatively; however, chewing is not allowed (soft diet) for 2 to 3 months to limit functional loading of the metal fossa. After 3 to 6 months, an occlusal equilibration is accomplished as needed.

**Results**

Medical chart review revealed 84 patients (5 males and 79 females), and 108 joints (24 bilateral, 60 uni-

lateral) were reconstructed with the Co-Cr-Mo glenoid fossa-eminence prosthesis (Christensen TMJ Implant System). The mean age at surgery was  $42 \pm 12$  years (range, 17 to 75 years). Mean preoperative symptom duration was 12.3 years (range, 1 to 55 years). Mean follow-up period (years between surgery and data collection) was 3.0 years (Table 2). The average number of previous surgical treatments in the patients who had previous TMJ surgery, excluding arthrocentesis or intracapsular steroid injection, was 1.9 (range, 0 to 7) for each joint. Ten joints (9.4%) had not received prior surgical treatment. More than half of the joints (55 of 108) had been treated surgically 2 or more times (Table 3).

Fifty-four patients (representing 61 joints) completed the questionnaire portion of the study. Mean satisfaction with the surgical result was  $8.3 \pm 2.0$  on a scale of 1 to 10. The most important cause for patient seeking surgical treatment was pain. Mean pain intensity before surgery and at the time of study was: pain (1) changed from 4.77 to 2.10 (pain experience, 1 to 6) and pain (2) changed from 7.60 to 2.95 (1 to 10 visual analog scale [VAS]) (Table 1). These

**TABLE 2. FOLLOW-UP PERIOD (n = 93 JOINTS)\***

0 to 1 year, 18 (19.4%)	4 to 5 years, 14 (15.1%)
1 to 2 years, 17 (18.3%)	5 to 6 years, 12 (12.9%)
2 to 3 years, 15 (16.1%)	6 to 7 years, 5 (5.4%)
3 to 4 years, 10 (10.8%)	7 to 8 years, 2 (2.2%)

NOTE. Total is 100.2%, rounded to the first decimal place.

\*Mean follow-up period was 3.0 years.

**TABLE 3. NUMBER OF PREVIOUS SURGERIES (n = 108 JOINTS)\***

	0	1	2	$\geq 3$
No. of joints	10 (9.3%)	43 (39.8%)	31 (28.7%)	24 (22.2%)

\*The average number of previous temporomandibular joint surgeries was 1.9 (0 to 7 range).

**TABLE 4. CLINICAL FINDINGS (n = 59 TO 61 JOINTS)\***

	Preoperative (A)	Postoperative (B)	Mean Difference	(A - B)/A	P, paired <i>t</i> test
Pain 1 (n = 61) (1 to 6) (see Methods)	4.77 ± 1.45	2.10 ± 1.60	2.67	56.0%	<.0001
Pain 2 (n = 61) (1 to 10) VAS	7.60 ± 2.31	2.95 ± 2.35	4.65	61.2%	<.0001
Chewing ability (n = 61) (1 to 10) VAS	7.08 ± 2.62	3.30 ± 2.49	3.78	53.4%	<.0001
Jaw opening (n = 59) (1 to 10) VAS	6.57 ± 2.60	3.27 ± 2.42	3.30	50.2%	<.0001
Noise (n = 60) (1 to 10) VAS	6.28 ± 3.63	2.26 ± 2.49	4.02	64.0%	<.0001

\*Mean satisfaction with the surgical result was 8.3 ± 2.0 (on a visual analog scale [VAS] of 1 to 10, in 61 joints).

differences of 2.67 and 4.65 reduction reflect a 56% and 61.2% improvement in pain experience/intensity reduction, respectively (as measured by the 2 pain evaluation tests, 1 and 2). Likewise, scores pertaining to improved chewing ability (53.4%; from 7.08 to 3.30 on 1 to 10 VAS), increased jaw opening (50.2%; from 6.57 to 3.27 on 1 to 10 VAS), and reduced joint noise (64%; from 6.28 to 2.26 on 1 to 10 VAS) were recorded by patients. All data stated above were statistically significant ( $P < .01$ ) (Table 4). Questionnaire scores were not influenced by prior number of surgeries or previous graft materials (Tables 5, 6).

Estimated blood loss and anesthesia time on 84 patients (108 joints) were 1) mean estimated blood loss per joint was 86.8 ± 64.7 mL, 2) mean anesthesia time per joint was 157.7 ± 41.6 minutes; and 3) mean hospitalization time was 1.9 ± 0.7 days (includes day of surgery). Temporary seventh nerve weakness was recorded by patients on 11 joints; all patients denied seventh nerve deficit at 1 year postoperatively. Thirty-five patients reported initial occlusal changes; this number reduced to 12 joints 1 year or longer after surgery. A majority of the remaining 12 joints with occlusal changes required minor occlusion equilibra-

tion; however, 3 patients required orthodontic, orthognathic surgery, or prosthetic rehabilitation to normalize their occlusion (Table 8).

Nine (8.0%) fossa-eminence prostheses placed during the study period were removed during the study period: 4 were removed due to persistent pain, 3 were removed due to prosthesis looseness and secondary inflammation, and 2 were removed due to recurrent heterotropic bone formation. In 1 patient, both joints were reentered, debrided, and closed without removing the metal fossa (Table 8).

## Discussion

The results of this case series suggest that reduction in pain experience/intensity and improvements in mandibular function may be related to the placement of the metal fossa-eminence hemijoint prosthesis. These data suggest that an interpositional metallic TMJ joint prosthesis may be beneficial in patients with advanced degenerative arthritis, bone-on-bone contact (crepitus with function), and pain secondary to osteochondritis. We hypothesize that the properly stabilized flat metal fossa-eminence significantly changes the biomechanics of the TMJ by eliminating the obstructing effect of the eminence and allowing nontraumatized function. The surgical procedure morbidity is substantially less invasive and time consuming with the interpositional metal fossa implant than the total joint prosthetic replacement procedure as the mandible and associated musculature are left undisturbed except for the superior aspect of the condyle, which is frequently recontoured. In the multioperated chronic pain patient, the reduced surgical manipulation may also be a positive factor if the focal joint pain and joint mechanics are substantially improved. If chronic diffuse neuropathic pain or persistent myofascial pain persists and can be identified, they may be more effectively managed. The potential for postsurgical scarring and localized wound is-

**TABLE 5. PREVIOUS GRAFT MATERIALS (108 JOINTS, 84 PATIENTS)**

Group	No. of Joints	No. of Patients
1. Proplast/Teflon*	24 (22.2%)	18 (21.4%)
2. Metal prosthesis†	12 (11.1%)	8 (9.5%)
3. Silicone or Silastic‡§	27 (25.0%)	23 (27.4%)
4. Autogenous graft	10 (9.3%)	5 (6.0%)
5. No previous graft	35 (32.4%)	30 (35.7%)
Total	108 (100%)	84 (100%)

\*Vitek Inc, Houston, TX.

†Excludes group 1.

‡Silastic, Dow Corning, Midland, MI.

§Excludes group 1 and 2.

||Excludes group 1 to 3.

**TABLE 6. ONE-FACTOR ANALYSIS OF VARIANCE SCHEFFE F-TEST**

		<i>P</i>		
		F Ratio	Value	Significance
Based on the previous graft materials				
	Pain (1)	0.953	.4409	NS
	Pain (2)	0.935	.451	NS
	Chewing ability	0.44	.7791	NS
	Jaw opening	0.34	.85	NS
	Noise	0.453	.77	NS
Based on the number of prior surgeries				
	Pain (1)	1.433	.2429	NS
	Pain (2)	1.264	.296	NS
	Chewing ability	0.95	.423	NS
	Jaw opening	0.183	.9077	NS
	Noise	0.541	.6559	NS

Abbreviation: NS, not significant at 95%.

chemia is theoretically less with the more localized surgical manipulation compared with total joint reconstruction. Our impression is that the issue of metal fatigue fracture or joint wear products (and associated foreign body reaction) is avoided with the metallic hemijoint (fossa-eminence) replacement. Anecdotally, we have observed normal healing of the surgically recontoured condyle provided it is not abnormally loaded postsurgically; this entails creating proper vertical space for the metal fossa-eminence and using a flat prosthesis design to avoid articular eminence loading with anteroposterior mandibular motion.

A number of reports discuss pain and disability in patients with displaced or absent (discectomy) discs.<sup>3,4,32-37</sup> There is disagreement among authors relative to the need for disc replacement after discectomy. Long-term studies document minimal problems in patients after discectomy without replacement.<sup>32-34</sup> Other studies document poor long-term results after discectomy, and these authors advocate replacement with autogenous material such as fascia, dermis, muscle, or cartilage.<sup>8-11</sup> The long-term results with autogenous materials are at best unpredictable. The soft allogenic material for disc replacement has also been controversial until recent studies documented pre-

**TABLE 7. SEVENTH NERVE DEFICIT: BITE CHANGE (N = 57 JOINTS)**

	No. of joints	>1 Year
Difficulty in raising eyebrow	11	0
Change in bite	35	12

**TABLE 8. ETIOLOGY OF IMPLANT REMOVAL (9/112 JOINTS, 8.0%, 84 PATIENTS)**

Pain	4
Prosthesis loosening	3
Perijoint calcification (hypertropic)	2

dictable material particulation and secondary foreign body granuloma formation. All of these allogenic materials are banned from future use and removal is recommended.<sup>2,13,14,17,38-42</sup> Unfortunately, this group of patients continues to have significant morbidity, especially when reconstructive efforts are attempted to restore lost anatomy and function.<sup>13</sup> The total joint prosthesis for TMJ reconstruction has been advocated for the group of patients treated in this study.<sup>17,22-27,31</sup> These authors contend that anatomic derangement and dysmorphic joint alterations (condyle, disc, fossa-eminence) from various causes warrant total joint replacement. The total joint prosthesis has well-documented complications, including wear products and associated human immune response, limitation of motion from scarring and muscle contracture, heterotrophic bone formation, and component fracture or loosening.<sup>26,27,40,43</sup> Thus, a key question addressed in this study is whether the patient with documented advanced and painful degenerative arthritis of multiple etiologies, with a history of multiple TMJ operations, will respond favorably to partial joint replacement as described in this report. If so, significant cost and surgical morbidity may be reduced compared with reports highlighting problems associated with total joint replacement.

Patients were carefully selected by a multidisciplinary team for the metal fossa-eminence prosthesis procedure. The disc was absent or totally displaced in all patients documented either by magnetic resonance imaging and/or inferred by gross destruction of bony elements and joint space on computed tomography (CT). In addition, condyles were radiographically deformed in all patients and bone-on-bone contact was documented radiographically in all patients with CT scan of TMJs. This group of patients with advanced pathology is different than other groups reported where the Christensen metal fossa-eminence also produced positive therapeutic gains<sup>19,20</sup>; many of their patients were still classified as internal derangement patients.

The overall satisfaction score of  $8.3 \pm 2.0$  on a scale of 1 to 10 (mean follow-up period of 3.0 years) compared favorably with previous reports on outcome following metal fossa-eminence prosthesis placement.<sup>19,20,30</sup> Reduction in pain was qualitatively and quantitatively documented by patient questionnaires with overall improvements of 56% and 60.4%. Chase

et al<sup>19</sup> reported 73.4% improvement using the same metal fossa-eminence prosthesis after discectomy. Their patient population involved internal derangement patients so anatomic structures were not as severely compromised as were our multioperated patients with stage IV and V Wilkes classification. Mercuri et al<sup>27</sup> reported on 215 patients who had undergone TMJ reconstruction with a custom-fitted alloplastic total TMJ prosthesis. The patients were divided into 3 groups according to the number of prior unsuccessful surgeries. In subjective criteria, they found 52.7% improvement in pain over all groups. The patient population in this study would seem to compare favorably with our patient population.

Improvement in chewing ability (53.9%), in jaw opening (47.0%), and joint noise (63.7%) represented the same overall positive trend in our patient, which we believe translated to the overall surgical satisfaction score of 8.3 (on a scale of 1 to 10). Patient satisfaction scores in our patient population reflect the overall experience of patients and the impact of their operation compared with their preoperative status.

Previous authors<sup>24,27</sup> reported that with an increase in the number of surgical procedures before TMJ surgery, prospects for significant pain reduction and improvement in jaw function decline. We did not confirm this relationship in this study cohort. In addition, we could find no difference in subjective outcome based on the different graft materials used in previous TMJ surgeries for our patients.

An advantage of the metal fossa-eminence prosthesis is the lack of wear products and associated foreign body reaction. The condyle, we theorize, undergoes physiologic functional remodeling after surgery provided it is not simultaneously placed under nonphysiologic loading. A fibrous connective tissue layer we theorize is formed on the articulating surface of the condyle and metal prosthesis. This anatomic finding has been documented by the second author (E.E.K.) when removing the metal fossa-eminence for patients without tissue pathology but continued pain. The fibrous layer forms during active condylar motion in the absence of any anatomic obstruction or bone contact. Whenever placing the metal fossa-eminence implant, we reduce the inclination of the articular eminence and use implants with shallow angled eminence. Although theoretically the angle of inclination of the eminence should be restored, we are not convinced this is necessary, having previously observed that healing and functional remodeling of the condyle are adversely affected by a functional eminence in patients without a functional disc. Condylar superior surface resorption and remodeling are commonly observed in patients without a functioning disc of mul-

iple etiologies (postsurgical, post-traumatic, longstanding muscle dysfunction, and unknown). The smooth movement along the surface of the flat fossa-eminence implant without any interference is thought to be an important factor for success, and minimal condyle loading of the metal fossa implant facilitates its osseous healing and long-term stability. Long-term metal prosthesis stability (fibrointegration or osseointegration) is necessary for long-term success. Micromovement or macromovement of the prosthesis may induce inflammation and pain and, in this study cohort, led to the need for implant removal in 3 of our patients.

Compared with total joint reconstruction, partial or hemijoint replacement will theoretically reduce surgical morbidity. Operating time and blood loss per joint operated were favorable considering the severely compromised anatomy in our patient population. We were not able to find similar data in the literature for comparison.

Nine prostheses (8.0%) were removed in this study. Four prostheses were removed because of persistence of chronic disabling pain. Wolford et al<sup>25</sup> inferred this type of pain might come from irreversible muscle pathology or a chronic pain disorder with central nervous system involvement. Milam<sup>14</sup> also reported that the chronically painful conditions observed in many patients with TMJ dysfunction, who had undergone multiple operations, might be caused by the effects of repeated surgical trauma of the region. Improved diagnostic skills should reduce the number of these unfortunate outcomes. Diagnostic criteria of radiographically documented bone-on-bone contact and presence of focal preauricular pain aggravated by joint loading may permit the selection of patients with greater prospects of pain reduction. We speculated that this pain reduction will be limited to that related to joint inflammation secondary to osteochondritis and bone-on-bone contact. The patient and clinician need to be acutely aware of this limited objective. Three prostheses were removed because of loosening, which correlated with the onset of preauricular pain and swelling. Surgical adaptation of the prosthesis to the underlying bone is thought to be an important factor in preventing this complication.

Patients were encouraged to exercise the mandible after recovery from general anesthesia, to avoid hematoma formation, dense scarring, and secondary hypertrophic bone formation.<sup>25,43</sup> Two prostheses were removed because of hypertrophic bone formation, which is usually associated with recurrence of pain and limitation of motion. Early and vigorous range of motion exercises after surgery and placement of autogenous fat in the dead space of the wound are reported to reduce or eliminate this very difficult problem.<sup>44</sup>

Seventh nerve injury is a significant risk for patients undergoing TMJ reconstruction, especially those who have undergone previous multiple surgeries. Many of the patients with previous multiple surgeries had difficulty in determining the time of onset of this problem, thus complicating accurate assessment of symptoms of seventh nerve dysfunction. Importantly, no patient reported seventh nerve dysfunction after 1 year. A high number (61.4%) of our patients who reported postoperative occlusal change is commonly found in patients undergoing partial (hemi) or total TMJ reconstruction. These occlusal changes were present immediately after surgery and were likely secondary to the osseous recontouring and debridement of the condylar head and fossa at the time of joint arthrotomy. After 1 year of healing and functional adaptation, this percentage was reduced to 12 patients. Occlusal equilibration was required in all 12 patients with persistent occlusal premature contacts; however, 3 of these patients eventually required prosthetic reconstruction or orthognathic surgery.

The authors readily acknowledge that this is a retrospective study that was uncontrolled and relied on patient questionnaire. Results of this study support our current more rigorous design intended to examine patient selection and long-term surgical outcomes. Thus, this retrospective case series was designed as a preliminary examination of the outcome of hemijoint replacement in a heterogenous cohort study with an anticipated high degree of preoperative and postoperative morbidity. Our clinical impression of a high degree of therapeutic gains was confirmed by the results, especially the overall patient satisfaction of outcome data.

Caution in interpretation of the questionnaire results is warranted. These data are retrospective and based in large part on patient impressions of historical events, including recollection of preoperative pain intensity. Accuracy of pain memory is influenced by a number of factors that we did not address here; however, their current assessment of pain, function, and treatment satisfaction should be a reasonably accurate measurement. Finally, the study was not controlled or blinded and may therefore be subject to biases of the authors. We wish to highlight that the intent of this study was to generate information that would either support or discourage a more extensive prospective study design.

Finally, in an article by Fischer et al,<sup>45</sup> it was found that "retrospective measures were more sensitive to change than serial measures and correlated more strongly with patient satisfaction with change." Their patients were patients with arthritis who received self-management, drug, or surgical treatment. Their results of the patient's view of outcome lend some credence to our retrospective data.

Surgical placement of the TMJ metal fossa-eminence prosthesis (hemijoint replacement) provided symptomatic relief in our study cohort, as measured by patient ratings of pain, jaw function, and joint noise.

The results of this study are clearly preliminary and retrospective and require a more vigorous prospective analysis and data collection.

## References

1. Ross JB: The intracapsular therapeutic modalities in conjunction with arthrography: Case reports. *J Craniomandib Disord Fac Oral Pain* 3:35, 1989
2. American Association of Oral and Maxillofacial Surgeons: Recommendations for management of patient with temporomandibular joint implants: A workshop on temporomandibular joint implant surgery. *J Oral Maxillofac Surg* 51:1164, 1993
3. Dolwick MF: The role of temporomandibular joint surgery in the treatment of patients with internal derangement. *Oral Surg Oral Med Oral Pathol* 83:150, 1997
4. Sato S, Sakamoto M, Kawamura H, et al: Long term changes in clinical signs and symptoms and disc position and morphology in patient with nonreducing disc displacement in the temporomandibular joint. *J Oral Maxillofac Surg* 57:23, 1999
5. Wilkes CH: Surgical treatment of internal derangements of the temporomandibular joint. *Arch Otolaryngol Head Neck Surg* 117:64, 1991
6. Cosme GE: Eminectomy associated with redirectioning of the temporal muscle for treatment of recurrent TMJ dislocation. *J Craniomaxillofac Surg* 15:355, 1987
7. Macintosh RB: The use of autogenous tissues for temporomandibular joint reconstruction. *J Oral Maxillofac Surg* 58:63, 2000
8. Meyer RA: The autologous dermal graft in temporomandibular joint disc surgery. *J Oral Maxillofac Surg* 46:948, 1988
9. Pogrel MA, Kaban LB: The role of a temporalis fascia and muscle flap in temporomandibular joint surgery. *J Oral Maxillofac Surg* 48:14, 1990
10. Wong T, Jin Y, Laskin DM: Autologous pericranial graft resurfacing after high condylectomy and discotomy of the temporomandibular joint in rabbits. *J Oral Maxillofac Surg* 54:747, 1996
11. Chossegras C, Guyot L, Cheynet J, et al: Comparison of different materials for interposition arthroplasty in treatment of temporomandibular joint ankylosis surgery: Long-term follow up in 25 cases. *Br J Oral Maxillofac Surg* 35:157, 1997
12. Stuteville OH, Lanfranchi RP: Surgical reconstruction of the temporomandibular joint. *Am J Surg* 90:940, 1955
13. Henry CH, Wolford LM: Treatment outcomes for temporomandibular joint reconstruction after Proplast-Teflon implant failure. *J Oral Maxillofac Surg* 51:352, 1993
14. Milam SB: Failed implants and multiple operations. *Oral Surg Oral Med Oral Pathol Oral Radiol Endod* 83:156, 1998
15. Black J, Sholtes V: Biomaterial aspects of surface replacement arthroplasty of the hip. *Ortho Clin North Am* 13:709, 1982
16. Lim LA, Carmichael SW, Cabanela ME: Biomechanics of total hip arthroplasty. *Anat Rec* 257:110, 1999
17. Mercuri LG: Alloplastic temporomandibular joint reconstruction: Review article. *Oral Surg Oral Med Oral Pathol* 85:631, 1998
18. VanLoon JP, DeBont LGM, Boering G: Evaluation of temporomandibular joint prostheses: Review of the literature for 1946-1994 and implications for future designs. *J Oral Maxillofac Surg* 53:984, 1995
19. Chase DC, Russell R, Latta JE, et al: The Christensen prosthesis: A retrospective clinical study. *Oral Surg Oral Med Oral Pathol* 80:273, 1995
20. McLeod NMH, Saeld NR, Hensker R: Internal derangement of the temporomandibular joint treated by discotomy and hemiarthroplasty with a Christensen fossa-eminence prosthesis. *Br J Oral Maxillofac Surg* 39:63, 2001

21. Gerard DA, Curry J, Latta J, et al: Clinical study of 64 consecutive patients receiving the Christensen prosthesis. *Int J Oral Maxillofac Surg* (in press)
22. Dingwerth DJ, Wolford LM, Talwar RM, et al: Comparison of two total joint prosthesis systems used for TMJ reconstruction. *J Oral Maxillofac Surg* 56:59, 1998 (suppl 4)
23. Mercuri LG: The use of alloplastic prostheses for temporomandibular joint reconstruction. *J Oral Maxillofac Surg* 58:70, 2000
24. Mercuri LG, Wolford LM, Sanders B, et al: Custom CAD/CAM total temporomandibular joint reconstruction system: Preliminary multicenter report. *J Oral Maxillofac Surg* 53:106, 1995
25. Wolford LM, Cottrell DA, Henry CH: Temporomandibular joint reconstruction of the complex patient with the Techmedica custom-made total joint prosthesis. *J Oral Maxillofac Surg* 52:2, 1994
26. Mercuri LG: The TMJ Concepts patient fitted total temporomandibular joint reconstruction prosthesis. *Oral Maxillofac Surg Clin North Am* 12:73, 2000
27. Mercuri LG: Subjective and objective outcomes in patients reconstructed with a custom-made alloplastic temporomandibular joint prosthesis. *J Oral Maxillofac Surg* 57:1427, 1999
28. Salter RB: *Continuous Passive Motion*. Baltimore, MD, Williams and Wilkins, 1993, pp 381-397
29. Smith AE, Robinson M: A new surgical procedure for the creation of a false temporomandibular joint in cases of ankylosis by means of a non-electrolytic metal. *Am J Surg* 94:837, 1957
30. House LR, Morgan DH, Hall WP: Temporomandibular joint surgery: Results of a 14-year joint implant study. *Laryngoscope* 94:534, 1984
31. McLeod NMH, Saeld NR, Hensker R: Temporomandibular joint replacement in rheumatoid-induced disease. *Br J Oral Maxillofac Surg* 39:71, 2001
32. Wilkes CH: Internal derangements of the temporomandibular joint: Pathological variation. *Arch Otolaryngol Head Neck Surg* 115:496, 1989
33. Ericksson L, Westesson P-L: Long-term evaluation of meniscectomy of the temporomandibular joint. *J Oral Maxillofac Surg* 43:263, 1985
34. Eriksson L, Westesson P-L: Discectomy as an effective treatment for painful temporomandibular joint internal derangement: A 5-year clinical and radiographic follow-up. *J Oral Maxillofac Surg* 59:750, 2001
35. Silver CM: Long-term results of meniscectomy of the temporomandibular joint. *J Craniomandib Pract* 3:46, 1984
36. Ericksson L, Westesson P-L: Discectomy in the treatment of anterior disk displacement of the temporomandibular joint: A clinical and radiographic one-year follow-up study. *J Prosthetic Dent* 55:106, 1986
37. Marciani RD, Ziegler RC: Temporomandibular joint surgery: A review of fifty-one operations. *Oral Surg Oral Med Oral Pathol* 56:472, 1983
38. Chuong R, Piper M, Boland TJ: Recurrent giant cell reaction to residual Proplast in the temporomandibular joint. *Oral Surg Oral Med Oral Pathol* 76:16, 1993
39. Raphael KG, Marbach JJ, Wolford LM: Self-reported systemic, immune-mediated disorders in patients with and without Proplast-Teflon implants of the temporomandibular joint. *J Oral Maxillofac Surg* 57:364, 1999
40. Kent JN: An important lesson about biomaterials in the TMJ. *J Oral Maxillofac Surg* 49:442, 1991 (letter to the editor)
41. Trumpy IG, Roald B, Lyberg T: Morphologic and immunohistochemical observation of explanted Proplast-Teflon temporomandibular joint interposition implants. *J Oral Maxillofac Surg* 54:63, 1996
42. Trumpy IG, Lyberg T: Surgical treatment of internal derangement of the temporomandibular joint: Long-term evaluation of three techniques. *J Oral Maxillofac Surg* 53:740, 1995
43. Lindqvist C, Soderholm AL, Hallikainen D, et al: Erosion and N bone formation after alloplastic temporomandibular joint reconstruction. *J Oral Maxillofac Surg* 50:942, 1992
44. Wolford LM, Karras SC: Autologous fat transplantation around temporomandibular joint total joint prostheses: Preliminary treatment outcome. *J Oral Maxillofac Surg* 55:245, 1997
45. Fischer D, Stewart AL, Bloch DA, et al: Capturing the patients' view of change as a clinical outcome measure. *JAMA* 282:1157, 1999